

PEDIATRICS

OFFICIAL JOURNAL OF THE AMERICAN ACADEMY OF PEDIATRICS

COVID-19 Vaccination-Associated Myocarditis in Adolescents

Supriya S. Jain, MD, Jeremy M. Steele, MD, Brian Fonseca, MD, Sihong Huang MD, MMsc, Sanket Shah MD, Shiraz A. Maskatia MD, Sujatha Buddhe, MD, MS., Nilanjana Misra MBBS, Preeti Ramachandran MD, Lasya Gaur MD, Parham Eshtehardi MD, Shafkat Anwar MD, Neeru Kaushik MD, Frank Han MD, Nita Ray Chaudhuri MD, Lars Grosse-Wortmann MD

DOI: 10.1542/peds.2021-053427

Journal: *Pediatrics*

Article Type: Regular Article

Citation: Jain SS, Steele JM, Fonseca B, et al. COVID-19 vaccination-associated myocarditis in adolescents. *Pediatrics*. 2021; doi: 10.1542/peds.2021-053427

This is a prepublication version of an article that has undergone peer review and been accepted for publication but is not the final version of record. This paper may be cited using the DOI and date of access. This paper may contain information that has errors in facts, figures, and statements, and will be corrected in the final published version. The journal is providing an early version of this article to expedite access to this information. The American Academy of Pediatrics, the editors, and authors are not responsible for inaccurate information and data described in this version.

COVID-19 Vaccination-Associated Myocarditis in Adolescents

Supriya S. Jain^a, MD, Jeremy M. Steele^b, MD, Brian Fonseca^c, MD,
Sihong Huang^d MD, MMsc, Sanket Shah^e MD, Shiraz A. Maskatia^f MD,
Sujatha Buddhē^g, MD, MS., Nilanjana Misra^h MBBS, Preeti Ramachandranⁱ MD,
Lasya Gaur^j MD, Parham Eshtehardi^k MD, Shafkat Anwar^l MD, Neeru Kaushik^m MD,
Frank Hanⁿ MD, Nita Ray Chaudhuri^o MD, Lars Grosse-Wortmann^p MD

Affiliations: ^aNew York Medical College, Maria Fareri Children's Hospital at Westchester Medical Center, Valhalla, New York, ^bYale University School of Medicine, New Haven, Connecticut, ^cColorado Children's Hospital, Aurora, Colorado, ^dHelen DeVos Children's Hospital, Michigan State University College of Human Medicine, Spectrum Health, Grand Rapids, Michigan, ^eChildren's Mercy Hospital, Kansas City, Missouri, ^fStanford University School of Medicine, Lucile Packard Children's Hospital, Palo Alto, California ^gSeattle Children's Hospital, University of Washington, Seattle, Washington, ^hCohen Children's Medical Center of New York, Northwell Health, Queens, New York, ⁱUniversity of Kentucky, Lexington, Kentucky, ^jJohn Hopkins School of Medicine, Baltimore, Maryland, ^kNorthside Heart and Vascular institute, Northside Hospital, Atlanta, Georgia, ^lUniversity of California at San Francisco, San Francisco, California, ^mUCSF Benioff Children's Hospitals, Oakland, California, ⁿUniversity of Illinois Chicago, College of Medicine at Peoria, Illinois, ^oWest Virginia University, Morgantown, West Virginia, ^pOregon Health and Science University, Portland, Oregon

Address correspondence to: Supriya S. Jain MD, Department of Pediatrics, Division of Pediatric Cardiology, New York Medical College, Maria Fareri Children's Hospital at Westchester Medical Center

100 Woods Road, Valhalla, New York, 10595, Sjain7@nymc.edu, 914-594-2222.

Conflict of Interest Disclosures (including financial disclosures): No conflicts of interest to disclose. (All authors)

Funding: This study was not supported by external funding.

Abbreviations: C-VAM: COVID-19 Vaccine Associated Myocarditis, COVID-19: Coronavirus Disease 2019, CDC: Centers for Disease Control and Prevention, VAERS: Vaccine Adverse Event Reporting System, mRNA: messenger ribonucleic acid, MIS-C: multisystem inflammatory syndrome in children, CMR: cardiac magnetic resonance imaging LGE: late gadolinium enhancement, ECV: extracellular volume, EGE: early gadolinium enhancement, IRB: Institutional review board, EF: Ejection fraction, RT-PCR: real-time reverse transcription polymerase chain reaction, SARS-COV-2: severe acute respiratory syndrome virus-2, ECG: Electrocardiogram, ECMO: extracorporeal membrane oxygenation, ICU: intensive care unit, ACE2: type 2 angiotensin-converting enzyme receptor, ACIP: Advisory Committee on Immunization Practices, FDA: U.S. Food and Drug Administration, EUA: Emergency Authorization Use

Article Summary: Large multi-center study affords us insight into characteristics, early outcomes and myocardial injury, noted on state-of-the-art CMR imaging in children with myocarditis after COVID-19 vaccination.

What's Known on This Subject: Based on the recent CDC data and smaller case series, there is a temporal association of the second dose of mRNA vaccines against COVID-19 with myocarditis.

What This Study Adds: It enhances our understanding into the spectrum, severity and associated myocardial tissue changes in COVID-19 vaccination associated myocarditis as compared to MIS-C. It provides valuable and timely follow up information in these children.

Contributors' Statements

Drs. Jain and Grosse-Wortmann conceptualized and designed the study, designed the data collection form, collected data, coordinated, and supervised data collection, carried out the analyses, drafted the initial manuscript, reviewed, and revised the manuscript.

Drs. Steele and Fonseca collected data, helped in editing the initial manuscript and figures, critically reviewed the manuscript for important intellectual content.

Drs. Huang, Shah, Maskatia, Buddhé, Misra, Ramachandran, Gaur, Eshtehardi, Anwar, Kaushik, Han and Chaudhuri collected data, critically reviewed the manuscript for important intellectual content.

All authors approved the final manuscript as submitted and agree to be accountable for all aspects of the work.

Abstract

Objective:

This study aimed to characterize the clinical presentation, short term prognosis, and myocardial tissue changes associated with acute myocarditis following COVID-19 vaccination in the pediatric population.

Methods:

In this retrospective multi-center study across 16 US hospitals, patients <21 years of age with a diagnosis of myocarditis following COVID-19 vaccination were included and compared to a cohort with multisystem inflammatory syndrome in children (MIS-C). Younger children with vaccine associated myocarditis were compared to older adolescents.

Results:

63 patients with a mean age of 15.6 years were included. 92% were male. All had received an mRNA vaccine and, except for one, presented following the 2nd dose. Four patients had significant dysrhythmia. 14% had mild left ventricular dysfunction on echocardiography which resolved on discharge. 88% met the diagnostic cardiac magnetic resonance (CMR) Lake Louise criteria for myocarditis. Myocardial injury was more prevalent in comparison to MIS-C patients. None of the patients required inotropic, mechanical, or circulatory support. There were no deaths. Follow up data obtained in 86% of patients, at a mean of 35 days showed resolution of symptoms, arrhythmias, and ventricular dysfunction.

Conclusions:

Clinical characteristics and early outcomes are similar between the different pediatric age groups. There is evidence of myocardial inflammation and injury following mRNA COVID-19 vaccination as seen on CMR. The hospital course is mild with quick clinical recovery and excellent short-term outcomes. Close follow up and further studies are needed to understand the long-term implications and mechanism of these myocardial tissue changes.

Introduction

Recently, an association of mRNA based COVID-19 vaccine with myocarditis has been reported.¹⁻³ In June 2021, the Centers for Disease Control and Prevention (CDC) observed a rate of post-vaccine myocarditis that was higher in adolescents and young adults than the expected baseline.³ Thus far, only small case series in the pediatric population with rudimentary information about the myocardium have been reported.¹ The current study aimed to understand the spectrum and severity of this recently recognized condition in the young, to evaluate the associated myocardial tissue changes and to compare it to the degree of cardiac involvement seen in multisystem inflammatory syndrome in children (MIS-C).

Methods

Following the initial reports of a possible association between COVID-19 vaccines and myocarditis, a call went out to physicians who specialize in cardiovascular imaging around the nation to report such cases from their institution to this retrospective study. Most investigators are clinical pediatric cardiologists and cardiac magnetic resonance (CMR) experts. The cases were reported to CDC's Vaccine Adverse Event Reporting System (VAERS) at the respective centers. The local research ethics boards of several of the participating centers issued an IRB exemption, while written informed consent was obtained from patients and/or their guardians at the others. Patients ≤ 21 years of age with a diagnosis of acute myocarditis, based on clinical presentation, abnormal biomarkers and/or cardiovascular imaging findings within 2 weeks of COVID-19 vaccination were included. Demographic information (including race/ethnicity to learn how different populations may be impacted), clinical presentation, cardiovascular imaging findings,

viral testing including comprehensive viral serology, hospital course, and follow-up information were collected. Patients with a plausible alternative etiology for their myocarditis including a concurrent acute viral infection were excluded.

From the CMR studies, ventricular volumes, and ejection fraction (EF) were obtained. The 2009 Lake Louise criteria⁴ or, where parametric mapping was available, the 2018 revised Lake Louise CMR criteria were used to test for a diagnosis of acute myocarditis.^{5,6} (Appendix). Evidence of myocardial edema was determined based on abnormally high signal intensity on T2-weighted imaging or prolonged T2 relaxation time on T2 mapping. Hyperemia was determined by myocardial early gadolinium enhancement (EGE). Native T1 times, extracellular volume (ECV) fraction and myocardial late gadolinium enhancement imaging (LGE) were collected as markers of cardiomyocyte injury and necrosis. Consistent with Society for Cardiovascular Magnetic Resonance guidelines, native T1 results were only used if institutional normal ranges were available and converted into categorical values.⁷ CMR image analysis and interpretation were done by the performing center to best reflect real-world practice. The study was not intended to identify and /or track pericarditis and focused on the clinical and imaging characteristics of COVID-19 vaccine associated myocarditis (C-VAM).

To gain perspective about the observed myocardial tissue changes, patients with a diagnosis of multisystem inflammatory syndrome in children (MIS-C) who had undergone CMR with a myocarditis protocol during their acute/sub-acute phase of illness were included for comparison from few select centers. As obtaining CMR data in the acute phase of illness in MIS-C had been

logistically challenging earlier due to the risk of exposure of severe acute respiratory syndrome virus- 2 (SARS-COV-2) to others, this data was limited ⁸

Statistical Analysis: Data are presented as means and standard deviations if normally distributed, as medians and ranges otherwise, or as counts and percentages as applicable. Older vs. younger adolescents with C-VAM and patients with MIS-C vs. C-VAM were compared using unpaired, two-tailed Student T tests. P values <0.05 were regarded as statistically significant.

Results

Clinical Characteristics

Sixty-nine cases of patients with a diagnosis of acute myocarditis following COVID-19 vaccination who had presented between March 2021 and June 2021 were submitted from 16 institutions. Six patients were excluded with a possible concurrent acute infection which could have caused the myocarditis. Sixty-three patients with a mean age of 15.6 ± 1.8 years (range 12-20 years) were included. Thirty-one patients (49%) were in the 12-15 age group. Fifty-eighty patients (92%) were male. Forty-three (68%) were White, 9 (14%) were Hispanic, 3 (5%) of Asian descent, 2 (3%) reported as other and 6 (10%) were unreported. All patients had been previously healthy before receiving the vaccine, without any viral prodrome. None of the patients had a history of or reactions to prior vaccines. Fifty-five (87%) had no significant past medical history. Pertinent past medical history in seven patients included a remote history of viral myocarditis in two patients, juvenile idiopathic arthritis, eosinophilic esophagitis, hyperlipidemia, irritable bowel syndrome and Wolff-Parkinson-White syndrome in one each.

One patient had a history of mild COVID-19 infection six months prior to his first dose of vaccine with no residual symptoms. There was a family history of viral myocarditis and Brugada syndrome in one patient each. Fifty-nine patients (94%) had received the Pfizer-BioNTech vaccine and four (6%) had received the Moderna vaccine. All except for one patient presented following the 2nd dose. The patient who presented after the initial dose had no known prior COVID-19 infection.

Mean onset of symptoms from day of vaccination was 2.1 ± 1.3 days (range 0-7 days). Forty-five patients (71%) presented with symptoms within two days of receiving the vaccine. Predominant symptoms are summarized in Table 1. All patients displayed elevated serum troponin levels and all, but one had abnormal C-reactive protein levels. Approximately half of the patients had an elevated erythrocyte sedimentation rate (44%) and/or B-natriuretic peptide (53%). Acute COVID-19 infection was ruled out based on a negative real-time reverse transcription polymerase chain reaction (RT-PCR) test to detect SARS-COV-2 in 56 patients (89%); the others were not tested. Past exposure to COVID-19 infection was ruled out based on negative nucleocapsid antibody test in 53 (84%) patients. Of these, 18 patients were positive for spike protein, suggesting an active immune response to the vaccine.

The length of stay in the hospital was 3.0 ± 1.4 days (range 1-7). Twenty-seven (43%) patients were supervised in the intensive care unit (ICU) during their hospitalization, mainly for arrhythmia monitoring with a mean stay of 2.5 days. None of the patients required inotropic support, mechanical ventilation, or extracorporeal membrane oxygenation (ECMO). There were

no deaths. Treatments included nonsteroidal anti-inflammatory drugs in 54 patients (86%), intravenous immunoglobulin in 17 (23%), corticosteroids in 15 (24%) and colchicine in four (6%). Six patients (10%) had received aspirin, clopidogrel, nitroglycerine, heparin, or beta blocker due to concerns for ST- segment elevation myocardial infarction on presentation.

Cardiovascular Findings

Forty-four patients (70%) had abnormal electrocardiograms (ECGs). Predominantly diffuse ST segment elevations and/or T wave inversion were noted (Figure 1). One patient (2%) presented with complete heart block but did not require pacing and regained normal conduction following admission. Three (5%) patients were noted to have non-sustained ventricular tachycardia, of which one was treated with amiodarone (Figure 2), and another with an oral beta-blocker.

Nine patients (14%) had mildly decreased left ventricular function (EF 45-54%) by echocardiography (Table 2). Coincidental findings on echocardiography included bicuspid aortic valve and an anomalous origin of the right coronary artery from the left sinus of Valsalva in one patient each. Fifty-six patients (89%) underwent CMR. The CMR study was performed within a week of the COVID-19 vaccination in 51 patients (91%). Fifty (89%) patients had evidence of myocardial edema based on T2-weighted imaging or T2 mapping (Figure 3). T1-weighted imaging to evaluate EGE denoting hyperemia was performed in 13 patients (21%) and was universally negative. Forty-nine patients (88%) had evidence of LGE (Figures 4&5) which occurred nearly uniformly in the inferolateral and lateral walls of the left ventricle in the sub-epicardial region, typical location encountered in myocarditis and a pattern consistent with non-

ischemic myocardial injury and necrosis.⁹ LGE were predominantly reported in the American Heart Association myocardial segments 4, 5, 6, 10, 11, 12 along with segments 1, 13, 14,15,16 in some patients.¹⁰ Mean ECV was $32.6\pm 9.0\%$. Thirteen patients (23%) had mildly reduced left ventricular function while three (7%) had mildly reduced right ventricular function. Mildly increased left ventricular volume was reported in one patient, while three had borderline/mild right ventricular dilation.^{11,12} Forty-nine patients (88%) fulfilled the CMR Lake Louise imaging criteria for myocarditis.

There was no significant difference in the clinical characteristics or the cardiovascular findings between the 12–15-year age group and the older adolescents in the C-VAM cohort (Table 1&2). On comparison of the patients with C-VAM to the MIS-C cohort (Table 3), the MIS-C patients were sicker with a longer ICU length of stay, 7 days ± 5 (2-18). 50% of them required inotropic support including ECMO in one. C-reactive protein was higher and ventricular function was worse when compared to patients with C-VAM. Serum troponin levels were higher and there was increase in prevalence and extent of LGE in the C-VAM group when compared to the MIS-C cohort (Figures 4, 5& 6)

Follow up

In patients with COVID-19 vaccine associated myocarditis, follow up data until July 21, 2021, was reviewed. There was no significant difference in the follow up/ short-term outcomes

between the younger and older pediatric age groups. Fifty-four patients (86%) were evaluated for follow up at a mean of 35 days \pm 25 (8-122) since their last vaccination. All were doing well clinically with resolution of their symptoms in most. Seven patients (13%) reported non-specific symptoms including intermittent atypical chest pain (4), palpitations (2) and mild fatigue with minimal activity (1). All patients had normal ventricular function, based on echocardiography. The 4 patients who had presented with arrhythmias earlier continue to be in normal sinus rhythm with no recurrence. Of the 60 patients with ECGs done at follow-up, 48 (80 %) had normal ECGs. Eight had persistent T wave abnormality/inversion in inferior leads, two had inferior Q waves, and two had non-specific ST-T changes. Holter information was available in 10 patients (19%) and revealed no abnormalities. Troponin levels were obtained in 27 patients (50%) and were normal, except three individuals had borderline elevations. 2 patients (4%) have had a follow up CMR so far at 66 and 71 days, respectively, after the initial CMR. Both showed improvement in myocardial edema but had persistence of LGE with mild improvement in one patient (Figure 7). Both patients continued to have normal biventricular function on CMR. Biventricular sizes were normal in both, including one who was noted to have mild right ventricular dilation at his initial CMR. Follow up CMR studies have been scheduled and are pending at the time of this submission for rest of the patients. There were no acute events, re-hospitalization or deaths reported.

Discussion

Although myocarditis following immunizations against smallpox, influenza, and tetanus is well recognized,¹³⁻¹⁶ the experience in children with vaccine associated myocarditis, other than following COVID-19 vaccination is limited. Importantly, myocarditis was not reported following

the clinical trials of mRNA COVID-19 vaccines.^{17,18} This may be related to the limited number of patients in the clinical trials and reflective of the apparent rarity of this complication.¹⁹

On May 10, 2021, the U.S. Food and Drug Administration (FDA) expanded the Emergency Authorization Use for the Pfizer-BioNTech vaccine to include adolescents 12 through 15 years age.²⁰ As of July 6, 2021, 594 cases of myocarditis/pericarditis reported to VAERS have been confirmed by CDC and FDA.²¹ Based on the Advisory Committee on Immunization Practices notification from June 23, 2021, the highest reporting rates were among males aged 12–17 years and those aged 18–24 years (62.8 and 50.5 reported myocarditis cases per million second doses of mRNA COVID-19 vaccine administered, respectively)²² At present, the CDC and FDA continue to recommend the COVID-19 vaccination for all individuals aged ≥ 12 years.²²

The present study adds the following information to our understanding of myocarditis related to the COVID-19 vaccine:

1. Myocarditis following mRNA vaccines is associated with acute myocardial injury and edema of the myocardium, in the presence of preserved ventricular function.
2. The initial clinical course and short-term outcomes are good and reassuring.
3. There is no apparent difference in clinical characteristics and outcomes between 12–15-year-olds and older adolescents.
4. The clinical picture is distinct from multisystem inflammatory syndrome in children (MIS-C) and appears to be less severe.

While endomyocardial biopsy remains the confirmatory test in the diagnosis of myocarditis, its invasive nature, and the possibility of tissue sampling errors along with risks of cardiac perforation and arrhythmias limit its use, especially in children. Cardiac magnetic resonance imaging has emerged as the modality of choice to evaluate the myocardium, including in myocarditis.^{4,23} The CMR diagnosis of myocarditis by the Lake Louise Criteria is based on the detection of myocardial edema and myocardial injury/necrosis.^{4,5,6,23,24} Majority of our patients met this CMR criteria, rest were classified as clinically suspected myocarditis.²³ Prior reports provided limited insights into the CMR findings in C-VAM. The myocardial tissue characteristics observed in our patients were like those seen in acute viral-mediated myocarditis^{4,23,24} Most patients presented with evidence of myocardial edema. Subepicardial LGE, affecting the left ventricular lateral and inferior walls was present in nearly all patients. The high prevalence of LGE and, in some cases, its extent along with consistency of LGE pattern (Figures 4 & 5) was unexpected, especially given the relatively mild clinical symptoms in many patients, although it was in keeping with the elevated troponin levels that were observed in all patients. The relatively mild disease course of the patients reported here makes it tempting to speculate that many others go undetected, as was the case with the smallpox vaccine.¹³⁻¹⁵

In contrast, patients with MIS-C are often critically ill on presentation requiring advanced support.²⁵⁻²⁸ They have higher systemic inflammatory markers and imaging evidence of cardio-depression. The C-VAM patients, with a milder presentation/hospital course and relatively preserved ventricular function appear to have increased prevalence of LGE in comparison to MIS-C. This raises the question if differing pathomechanisms of cardiac involvement are at play in C-VAM versus MIS-C. While it has been hypothesized that the acute ventricular dysfunction

complicating MIS-C may be related to the systemic cytokine storm that is present during this overwhelming inflammatory condition²⁵⁻²⁸, the mechanism of cardiac injury in C-VAM appears more targeted to the cardiomyocyte. The pathophysiology of the myocardial injury in these patients is not well understood. One proposed mechanism is through molecular mimicry²⁹⁻³¹: Myocardial proteins may resemble those which are expressed after mRNA vaccination, to which the body mounts an antibody response, possibly leading to myocardial injury/inflammation. The spike glycoprotein of SARS-COV-2 attaches to the myocardial type 2 angiotensin-converting enzyme (ACE2) receptor expressed by cardiomyocytes, directly causing cause cell membrane disruption, even at low viral load^{32,33} Thus as an alternative explanation of vaccine related injury, it is conceivable that in C-VAM patients, the myocardial injury may be the result of SARS-COV-2 spike protein encoded by the mRNA vaccine and its binding to the host cell ACE2 receptor³⁴ even in the absence of live virus. Lastly, it is possible that the complex of mRNA vaccine induced spike protein and myocardial ACE2 receptor presents an immunological target. In this context, the striking predilection for males, which is a consistent element of previous reports and corroborated by our results, is noteworthy: Less than 10% of our patients were female. Estrogen is known to upregulate ACE2³⁵ which has been proposed as a protective mechanism against organ damage by SARS-COV-2, including in the heart. An increased genetic susceptibility in some patients has been discussed³⁶ and may explain the recurrent myocarditis in two of our patients who had a previous episode and potentially a third with a family history of viral myocarditis.

Myocarditis after COVID-19 vaccination has been noted predominantly in White patients, in contrast to the Black and ethnic minority groups frequently reported in MIS-C^{25,27,28} Possible

explanations for this ethnic discrepancy may include socioeconomic disparities seen in COVID-19 infections³⁷, variation in vaccination rates,³⁸ as well as susceptibility to the infection itself and/or its complications.

Ten percent of our patients were initially worked-up and treated for myocardial infarction. As awareness of vaccine related myocarditis increases, we expect that more practitioners will consider the possibility of C-VAM, and the diagnosis will be made earlier.

A selection bias in the C-VAM cohort towards LGE positive patients cannot be ruled out in our study, given that LGE was likely used to establish a diagnosis of myocarditis in some individuals. In fact, a similar selection bias is likely present in most if not all CMR based studies of myocarditis. The true and independent prevalence of LGE is therefore unknown and we are unable to speculate whether LGE is more prevalent after vaccination as compared to viral myocarditis.

The prognostic significance of the prevalent LGE in asymptomatic C-VAM patients is unclear at this time. The follow up CMR in two of our patients has shown persistence of LGE, albeit mildly decreased in one. Some reports have suggested a contraction of LGE during follow-up of acute viral myocarditis.^{39,40} Follow up CMR hence appears warranted to depict the extent of myocardial and ventricular remodeling/resolution of LGE. In the absence of guidelines for return to sports after myocarditis following COVID-19 vaccination, our findings make it seem reasonable to apply the recommendations available for acute viral myocarditis which include refraining from sports for at least three to six months as well as close observation and monitoring for any dysrhythmias.⁴¹

Limitations of our study include its retrospective nature, combining patients from 16 different institutions which used similar, but not identical approaches during the work-up and management of childhood myocarditis. Our cases represent a selected cohort which may not necessarily be representative of the general pediatric population.

Conclusion

We report the largest study that we are aware of describing myocardial tissue characteristics in detail as noted on CMR with clinical features and early outcomes in pediatric patients with acute myocarditis following mRNA COVID-19 vaccination in the United States. Comparison with MIS-C improves our understanding of both the disease processes. Most patients with COVID-19 vaccine associated myocarditis had evidence of myocardial edema and of myocardial injury as evidenced by LGE which was out of keeping with the mild clinical presentation and normal or quickly recovered ventricular function in most. Early clinical outcomes in these patients have been reassuring so far. The prognostic significance, long-term implications and mechanism of this myocardial injury needs to be studied further, especially as vaccination efforts are rolled out to younger children.

Acknowledgments

Thank you to Dr. Michael H. Gewitz (Maria Fareri Children's Hospital at Westchester Medical Center) for his review of the manuscript and continued support.

References

1. Marshall M, Ferguson ID, Lewis P, et al. Symptomatic Acute Myocarditis in Seven Adolescents Following Pfizer-BioNTech COVID-19 Vaccination [published online ahead of print, 2021 Jun 4]. *Pediatrics*. 2021; e2021052478.
2. Staff T. Israel said probing link between Pfizer shot and heart problem in men under 30. The Times of Israel. <https://www.timesofisrael.com/israel-said-probing-link-between-pfizer-shot-and-heart-problem-in-men-under-30/>. Published April 23, 2021. Accessed June 20, 2021.
3. Shimabukuro T. COVID-19 Vaccine Safety Updates. June 10, 2021. Vaccines and Related Biological Products Advisory Committee (VRBPAC). <https://www.fda.gov/media/150054/download>. Published Jun 10, 2021. Accessed June 23, 2021.
4. Friedrich MG, Sechtem U, Schulz-Menger J, et al. Cardiovascular magnetic resonance in myocarditis: A JACC White Paper. *J Am Coll Cardiol*. 2009;53(17):1475-1487.
5. Ferreira VM, Schulz-Menger J, Holmvang G, et al. Cardiovascular Magnetic Resonance in Nonischemic Myocardial Inflammation: Expert Recommendations. *J Am Coll Cardiol*. 2018;72(24):3158-3176.
6. Luetkens JA, Faron A, Isaak A, et al. Comparison of Original and 2018 Lake Louise Criteria for Diagnosis of Acute Myocarditis: Results of a Validation Cohort. *Radiol Cardiothorac Imaging*. 2019;1(3): e190010. Published 2019 Jul 25.
7. Messroghli DR, Moon JC, Ferreira VM, et al. Clinical recommendations for cardiovascular magnetic resonance mapping of T1, T2, T2* and extracellular volume: A consensus statement by the Society for Cardiovascular Magnetic Resonance (SCMR) endorsed by the European Association for Cardiovascular Imaging (EACVI) [published correction appears in J Cardiovasc Magn Reson. 2018 Feb 7;20(1):9]. *J Cardiovasc Magn Reson*. 2017;19(1):75. Published 2017 Oct 9.
8. Jain S, Nolan S, Biller R, et al. Cardiovascular Magnetic Resonance in Myocarditis related to Multisystem Inflammatory Syndrome in Children Associated with COVID-19. *Congenital Cardiology Today*. 2020;20(8):7-9. Published 2020
9. Mahrholdt H, Wagner A, Judd RM, et al. Delayed enhancement cardiovascular magnetic resonance assessment of non-ischaemic cardiomyopathies. *Eur Heart J*. 2005;26(15):1461-1474. doi:10.1093/eurheartj/ehi258
10. Cerqueira MD, Weissman NJ, Dilsizian V, et al. Standardized Myocardial Segmentation and Nomenclature for Tomographic Imaging of the Heart: A Statement for Healthcare Professionals from the Cardiac Imaging *Circulation* 2002; 105:539-542
11. Kawel-Boehm N, Maceira A, Valsangiacomo-Buechel ER, et al. Normal values for cardiovascular magnetic resonance in adults and children. *J Cardiovasc Magn Reson*. 2015;17(1):29. Published 2015 Apr 18. doi:10.1186/s12968-015-0111-7
12. Alfakih K, Plein S, Thiele H, et al. Normal human left and right ventricular dimensions for MRI as assessed by turbo gradient echo and steady-state free precession imaging sequences. *J Magn Reson Imaging*. 2003;17(3):323-329. doi:10.1002/jmri.10262

13. Engler RJ, Nelson MR, Collins LC Jr, et al. A prospective study of the incidence of myocarditis/pericarditis and new onset cardiac symptoms following smallpox and influenza vaccination. *PLoS One*. 2015;10(3): e0118283. Published 2015 Mar 20.
14. Halsell JS, Riddle JR, Atwood JE, et al. Myopericarditis following smallpox vaccination among vaccinia-naive US military personnel. *JAMA*. 2003;289(24):3283-3289.
15. Eckart RE, Love SS, Atwood JE, et al. Incidence and follow-up of inflammatory cardiac complications after smallpox vaccination. *J Am Coll Cardiol*. 2004;44(1):201-205.
16. Yamamoto H, Hashimoto T, Ohta-Ogo K, et al. A case of biopsy-proven eosinophilic myocarditis related to tetanus toxoid immunization. *Cardiovasc Pathol*. 2018; 37:54-57.
17. Pfizer-BioNTech COVID-19 vaccine (BNT162, PF-07302048): Vaccines and Related Biological Products Advisory Committee briefing document. US Food and Drug Administration. <https://www.fda.gov/media/144246/download>. Published December 10, 2020. Accessed May 26, 2021.
18. Moderna mRNA-1273 sponsor briefing document for Vaccines and Related Biological Products Advisory Committee briefing document. US Food and Drug Administration. <https://www.fda.gov/media/144452/download>. Published December 17 2020. Accessed May 26, 2021.
19. Gubernot D, Jazwa A, Niu M, et al. U.S. Population-Based background incidence rates of medical conditions for use in safety assessment of COVID-19 vaccines. *Vaccine*. 2021;39(28):3666-3677.
20. Coronavirus (COVID-19) Update: FDA Authorizes Pfizer-BioNTech COVID-19 Vaccine for Emergency Use in Adolescents in Another Important Action in Fight Against Pandemic, FDA News release, May 10, 2021
21. Selected Adverse Events Reported after COVID-19 Vaccination, cdc.gov, updated July 7, 2021
22. Gargano JW, Wallace M, Hadler SC, et al. Use of mRNA COVID-19 Vaccine After Reports of Myocarditis Among Vaccine Recipients: Update from the Advisory Committee on Immunization Practices — United States, June 2021. *MMWR Morb Mortal Wkly Rep*. ePub: 6 July 2021. DOI: [http://dx.doi.org/10.15585/mmwr.mm7027e2external icon](http://dx.doi.org/10.15585/mmwr.mm7027e2external%20icon)
23. Law YM, Lal AK, Chen S, et al. on behalf of the American Heart Association Pediatric Heart Failure and Transplantation Committee of the Council on Lifelong Congenital Heart Disease and Heart Health in the Young and Stroke Council, Diagnosis and Management of Myocarditis in Children: A Scientific Statement From the American Heart Association. *Circulation*, July 7, 2021 (published ahead of print) <https://doi.org/10.1161/CIR.0000000000001001>
24. Banka P, Robinson JD, Uppu SC, et al. Cardiovascular magnetic resonance techniques and findings in children with myocarditis: a multicenter retrospective study. *J Cardiovasc Magn Reson*. 2015; 17:96. Published 2015 Nov 17.
25. Dufort EM, Koumans EH, Chow EJ, et al. Multisystem Inflammatory Syndrome in Children in New York State. *N Engl J Med*. 2020;383(4):347-358.

26. Friedman KG, Harrild DM, Newburger JW. Cardiac Dysfunction in Multisystem Inflammatory Syndrome in Children: A Call to Action. *J Am Coll Cardiol*. 2020;76(17):1962-1964. doi: 10.1016/j.jacc.2020.09.002
27. Jain S, Nolan SM, Singh AR, et al. Myocarditis in Multisystem Inflammatory Syndrome in Children Associated with Coronavirus Disease 2019 [published correction appears in *Cardiol Rev*. 2021 Jan/Feb;29(1):54]. *Cardiol Rev*. 2020;28(6):308-311.
28. Elias MD, McCrindle BW, Larios G, et al Management of Multisystem Inflammatory Syndrome in Children Associated With COVID-19: A Survey from the International Kawasaki Disease Registry, *CJC Open*. 2020 Nov; 2(6): 632–640. Published online 2020 Sep 11. doi: [10.1016/j.cjco.2020.09.004](https://doi.org/10.1016/j.cjco.2020.09.004)
29. Segal Y, Shoenfeld Y. Vaccine-induced autoimmunity: the role of molecular mimicry and immune crossreaction. *Cell Mol Immunol*. 2018;15(6):586-594. doi:10.1038/cmi.2017.151
30. D'Angelo T, Cattafi A, Carerj ML, et al. Myocarditis after SARS-CoV-2 Vaccination: A Vaccine-induced Reaction? [published online ahead of print, 2021 Jun 9]. *Can J Cardiol*. 2021; S0828-282X (21)00286-5.
31. Ammirati E, Cavalotti C, Milazzo A, et al. Temporal relation between second dose BNT162b2 mRNA Covid-19 vaccine and cardiac involvement in a patient with previous SARS-COV-2 infection. *Int J Cardiol Heart Vasc*. 2021; 34:100774.
32. Nishiga M, Wang DW, Han Y. et al. COVID-19 and cardiovascular disease: from basic mechanisms to clinical perspectives. *Nat Rev Cardiol* 17, 543–558 (2020).
33. Peng W, Wu H, Tan Y, et al. Mechanisms and treatments of myocardial injury in patients with corona virus disease 2019. *Life Sci*. 2020; 262:118496. doi: 10.1016/j.lfs.2020.118496
34. Kyriakidis NC, López-Cortés A, González EV, et al. SARS-CoV-2 vaccines strategies: a comprehensive review of phase 3 candidates. *npj Vaccines* 6, 28 (2021).
35. Bukowska A, Spiller L, Wolke C, et al. Protective regulation of the ACE2/ACE gene expression by estrogen in human atrial tissue from elderly men. *Exp. Biol. Med. (Maywood)* 242, 1412–1423 (2017).
36. Campuzano O, Fernández-Falgueras A, Sarquella-Brugada G, et al. A genetically vulnerable myocardium may predispose to myocarditis. *J Am Coll Cardiol*. 2015;66(25):2913–4. <https://doi.org/10.1016/j.jacc.2015.10.049>
37. Goyal MK, Simpson JN, Boyle MD, et al. Racial and/or Ethnic and Socioeconomic Disparities of SARS-CoV-2 Infection Among Children, *Pediatrics* October 2020, 146 (4) e2020009951; DOI: <https://doi.org/10.1542/peds.2020-009951>
38. Reporting COVID-19 Vaccination Demographic Data, [cdc.gov](https://www.cdc.gov), Updated June 28, 2021
39. Mahrholdt H, Goedecke C, Wagner A. Cardiovascular magnetic resonance assessment of human myocarditis; a comparison to histology and molecular pathology. *Circulation* 2004; 109:1250–1258
40. Friedrich MG, Strohm O, Schulz-Menger J. Contrast media-enhanced magnetic resonance imaging visualizes myocardial changes in the course of viral myocarditis. *Circulation* 1998; 97:1802–1809.

41. Maron BJ, Udelson JE, Bonow RO et al. Eligibility and Disqualification Recommendations for Competitive Athletes with Cardiovascular Abnormalities: Task Force 3: Hypertrophic Cardiomyopathy, Arrhythmogenic Right Ventricular Cardiomyopathy and Other Cardiomyopathies, and Myocarditis A Scientific Statement From the American Heart Association and American College of Cardiology. *Circulation* 2015;132: e273–e280 <https://doi.org/10.1161/CIR.0000000000000239>

Table 1: Clinical characteristics in children and young adults with myocarditis following COVID-19 vaccination

<i>Characteristic</i>	<i>Overall (n=63)</i>	<i>12-15 years (n=31)</i>	<i>16-20 years (n=32)</i>	<i>p-value</i>
Age (years)	15.6±1.8 (12-20)	14.4±1.1	16.9±1.0	
Height (cm.)	172±11	169±11	176±10	0.01
Weight (kg.)	73.3±19.4	67.5±16.6	79±20.5	0.02
BSA (m ²)	1.86±0.30	1.77±0.30	1.95±0.30	0.008
Male sex n, (%)	58 (92)	27 (87)	31 (97)	0.16
2nd dose n, (%)	62 (98)	30	32	0.32
Days from recent vaccination to symptoms onset	2.1±1.3 (0-7)	1.9±0.9 (1-3)	2.3±1.7 (0-7)	0.15
Symptoms: n, (%)				
Onset < 2 days since vaccination	45 (71)	22 (71)	23 (72)	0.94
Fever (100.4 F and above)	28 (44)	13 (42)	15 (47)	0.70
Shortness of breath	22 (35)	9 (29)	13 (41)	0.34
Chest pain	63 (100)	31 (100)	32 (100)	1.0
Nausea/Emesis	15 (24)	7 (23)	8 (25)	0.82
Headache	16 (25)	7 (23)	9 (28)	0.62
Fatigue/Myalgias/ Arthralgias	24 (38)	8 (26)	16 (50)	0.05

Laboratory values:

Troponin (ng/mL)	8.8±9.1	7.7 ±8.4	9.9± 9.9	0.34
C-reactive protein (mg/L)	37±35	28±23	46 ±43	0.05
BNP (pg/mL)	94±147	109±168	68±107	0.50

Treatment/Hospital course:

n/total n (%)

IVIG	17(23)	5(16)	12(38)	0.05
Steroids	15(24)	5(16)	10(31)	0.14
NSAIDs	54(86)	28(90)	26(81)	0.31
Colchicine	4(6)	1(3)	3(9)	0.32
ICU admissions n, (%)	27 (43)	10 (32)	17 (53)	0.09
Length of ICU in days	2.5±1.5 (1-7)	2.1±1.1 (1-4)	2.7±1.6 (1-7)	0.23
Length of hospital stay in days	3.0±1.4 (1-7)	2.8±1 (1-5)	3.3±1.7 (1-7)	0.18
Inotropic/mechanical/circulatory support, ECMO, Mortality	0			

*Data reported as mean, standard deviation, range unless specified.

Percentages may not total hundred because of rounding.

Unless otherwise specified, the denominator for calculation of percentages is the total sample size.

Abbreviations: BSA: Body surface area, BNP: B-natriuretic peptide, IVIG: Immunoglobulin, NSAIDs: Nonsteroidal anti-inflammatory drugs, ICU: intensive care unit

Table 2: Cardiovascular testing/imaging findings in children and young adults with myocarditis following COVID-19 vaccination

<i>Findings</i>	<i>Overall (n=63)</i>	<i>12-15 years (n=31)</i>	<i>16-20 years. (n=32)</i>	<i>p-value</i>
ECG: n (%)				
Abnormalities on ECG	44 (70)	19 (61)	25 (78)	0.38
Complete Heart Block	1 (2)	0 (0)	1 (3)	0.32
Non sustained VT	3 (5)	1 (3)	2 (6)	0.57
Echocardiography:				
LV EF %	61 ±6.5 (45-73)	61 ±6 (45-73)	60 ±7 (45-83)	0.51
Reduced LV EF, n, (%)				
Mild (EF:45-54%)	9 (14)	4 (13)	5 (16)	0.80
Moderate (EF:35-44%)	0			
Severe (EF <35%)	0			
CMR:				
Days from recent Vaccination to CMR	4.9±2.3 (2-15)	5.0 ±2.8 (2-15)	5.2 ±3.2 (2-15)	0.68
Myocardial Edema (T2 weighted imaging/T2 mapping) n, total n (%)	50/56 (89)	24/28 (86)	26/28 (93)	0.40
ECV%	32.6±9	36.3±11	28.9±4	0.05
Presence of LGE n, total n (%)	49/56 (88)	24/28(86)	25/28 (89)	0.69
LV EF %	58 ±6 (46-73)	59 ±6 (46-73)	57 ±5 (47-64)	0.21

Prepublication Release

Reduced LV EF, n, (%)				
Mild (EF:45-54%)	13/56 (23)	6/28 (21)	7/28 (25)	0.83
Moderate (EF:35-44%)	0			
Severe (EF <35%)	0			
LV EDV ml/m2	86±12 (55-111)	85 ± 11 (57-105)	88±14 (55-111)	0.40
RV EF %	56 ±9 (43-105)	56 ± 5 (47-65)	55 ±12 (43-105)	0.68
Reduced RV EF (EF<49%) n, total n (%)	3/45 (7)	1/22 (5)	3/23 (13)	0.58
RV EDV ml/m2	89± 15 (48-123)	87 ± 13 (56-107)	91± 16 (48-123)	0.36

*Data reported as mean, standard deviation, range unless specified.

Percentages may not total hundred because of rounding.

Unless otherwise specified, the denominator for calculation of percentages is the total sample size.

Abbreviations: ECG: Electrocardiogram, VT: Ventricular tachycardia, LV: Left ventricle, RV: Right ventricle, EF: ejection fraction, EDV: end-diastolic volume, CMR: cardiac magnetic resonance, ECV: extracellular volume, LGE: late gadolinium enhancement.

Table 3: Comparison between patients with mRNA COVID-19 vaccine associated myocarditis and MIS-C

	<i>C-VAM</i> <i>N=63</i>	<i>MIS-C</i> <i>N=16</i>	<i>P-VALUE</i>
Age (years)	15.6±1.8	13.3±4.3	0.05
Weight (kg)	73.3±19.4	57.1±20.8	0.01
Troponin (ng/ml)	8.78±9.15	0.67±1.10	<0.0001
C-reactive protein (mg/L)	37.0±35.4	151.1±119.5	0.002
Intensive care length of stay	2.5±1.5	6.6±4.6	0.004
LVEF % (echocardiography)	60.9±6.5	45.1±9.5	<0.0001
LGE (n, %)	49 (88)	3 (20)	0.0005
Myocardial edema* (n, %)	47 (83.9)	4 (28.6)	<0.0001

* As evidenced by CMR parametric mapping or T2 weighted imaging

Abbreviations: LGE: late gadolinium enhancement, LVEF: left ventricular ejection fraction, MIS-C: multisystem inflammatory syndrome in children, C-VAM: COVID-19 vaccine associated myocarditis

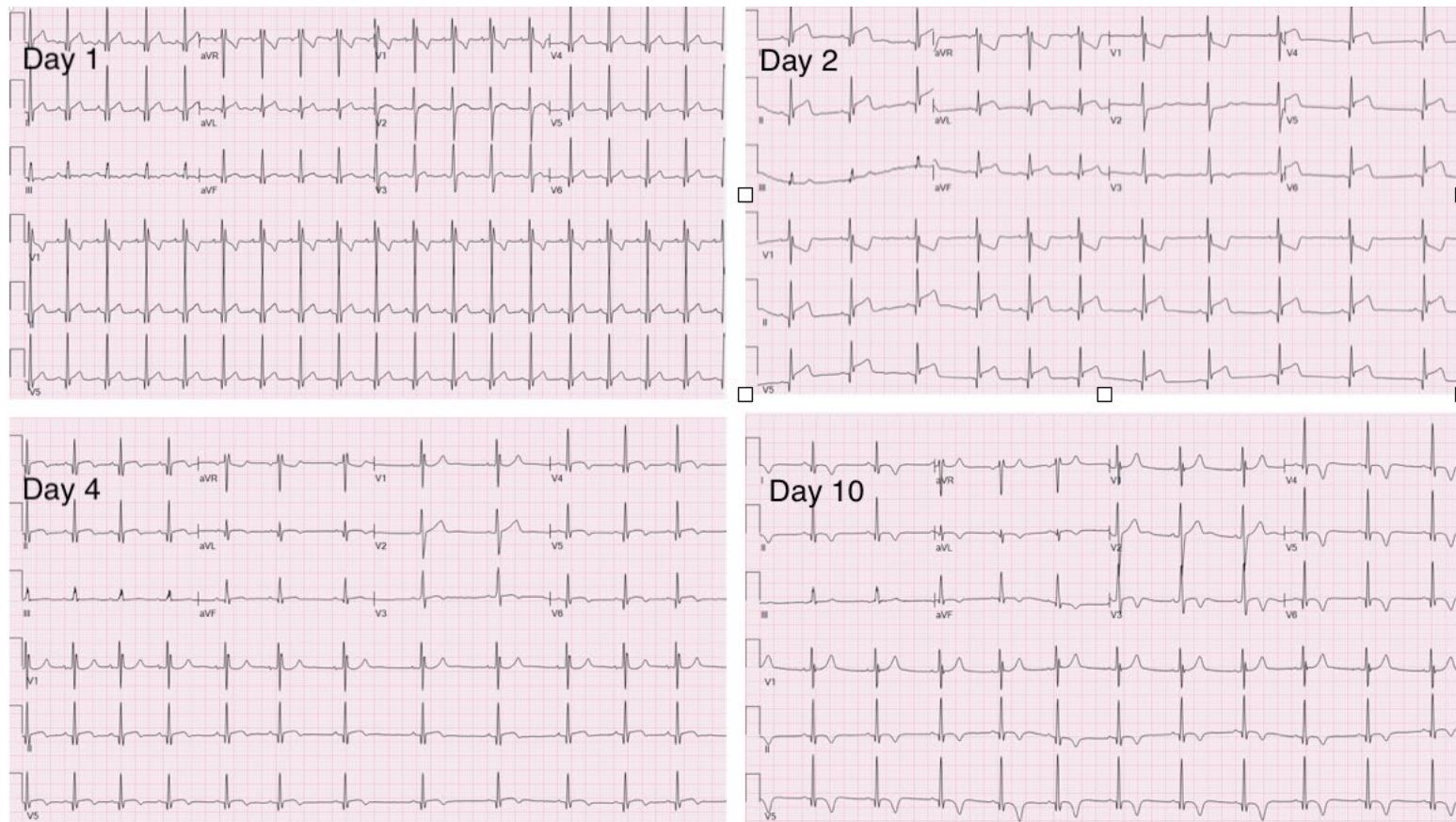


Figure 1. ECG in a 17-year-old patient with myocarditis following COVID-19 vaccination showing diffuse ST segment elevation (days 1, 2) and T wave inversion (days 4, 10)

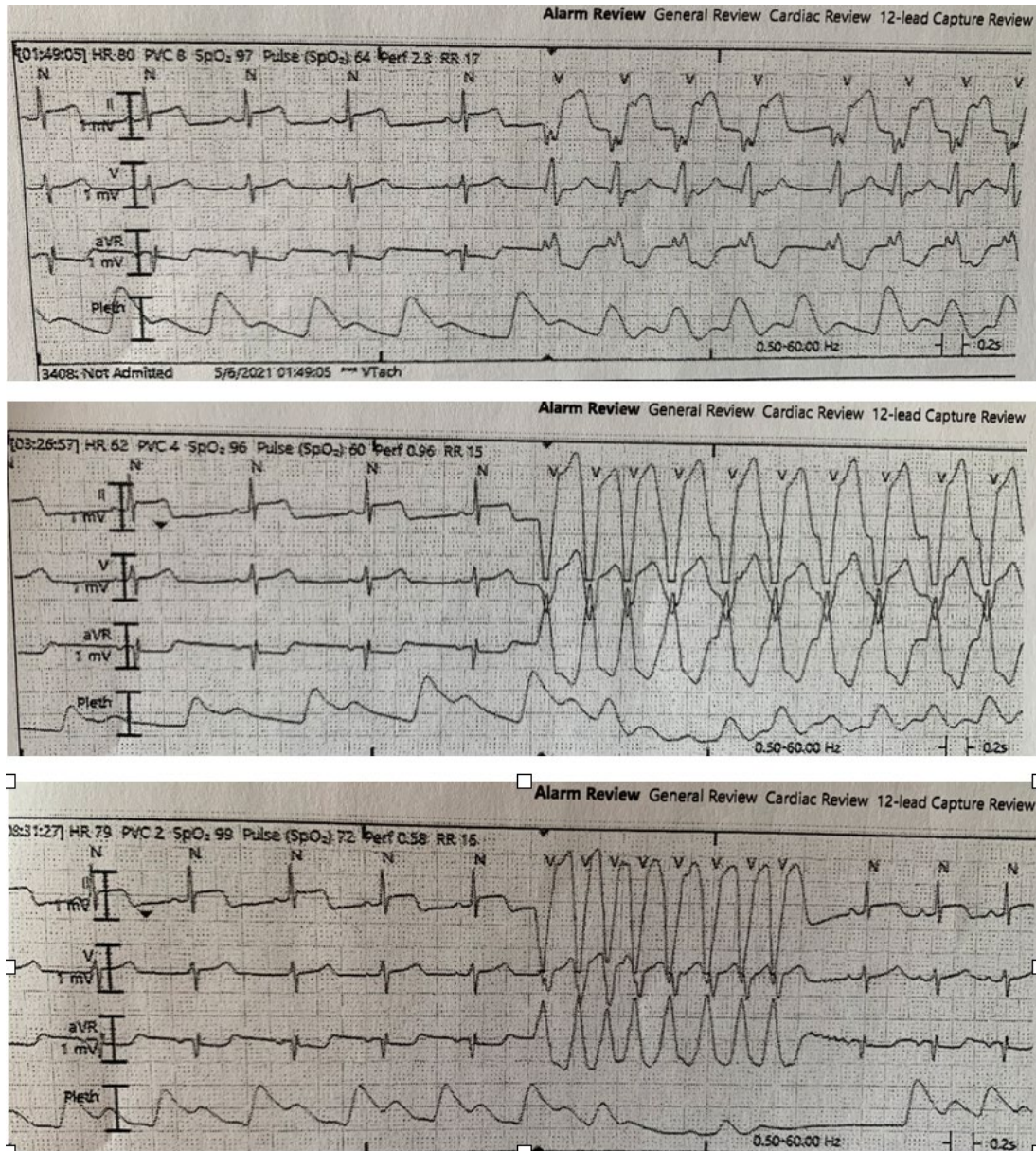


Figure 2. Strips from a telemetry unit showing multiple episodes of non-sustained ventricular tachycardia in a 16-year-old patient with myocarditis following COVID-19 vaccination.

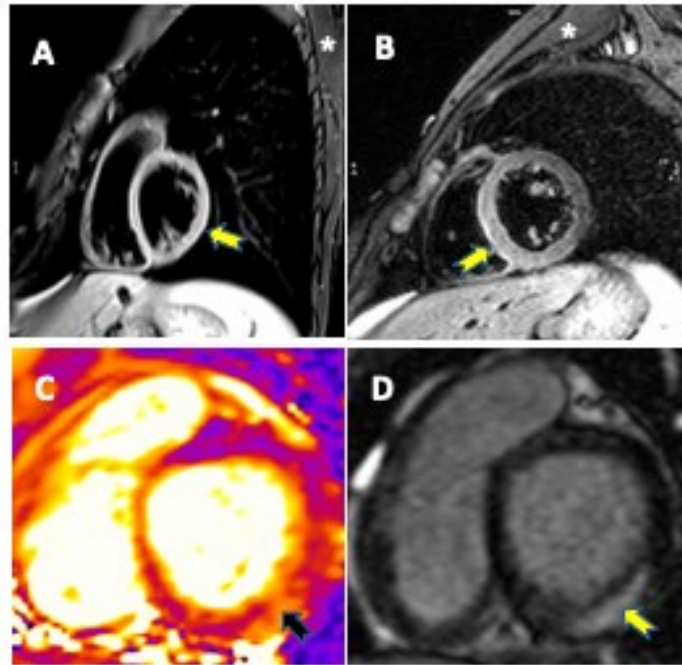


Figure 3. CMR examples of myocardial edema in C-VAM cohort:

(A, B) T2 weighted images show high signal intensity in myocardium (yellow arrow) compared to skeletal muscle (*) in 2 patients.

(C) T2 mapping image demonstrates area of elevated T2 (black arrow) in subepicardial, mid-myocardial region corresponding to (D) area of LGE (yellow arrow)

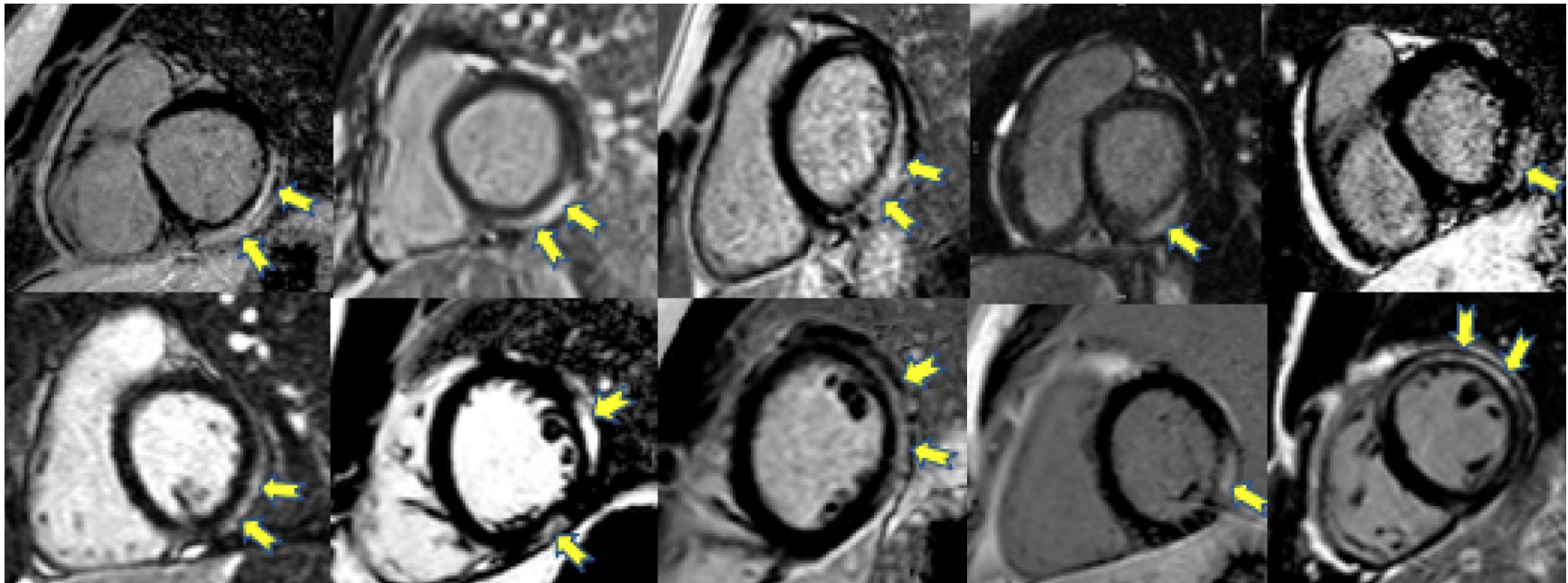


Figure 4. CMR examples illustrating LGE in C-VAM cohort (short axis view): The pattern of LGE is notably similar across all patients with a subepicardial distribution along the lateral, inferolateral and inferior walls in the basal and mid myocardium of the left ventricle (yellow arrows).

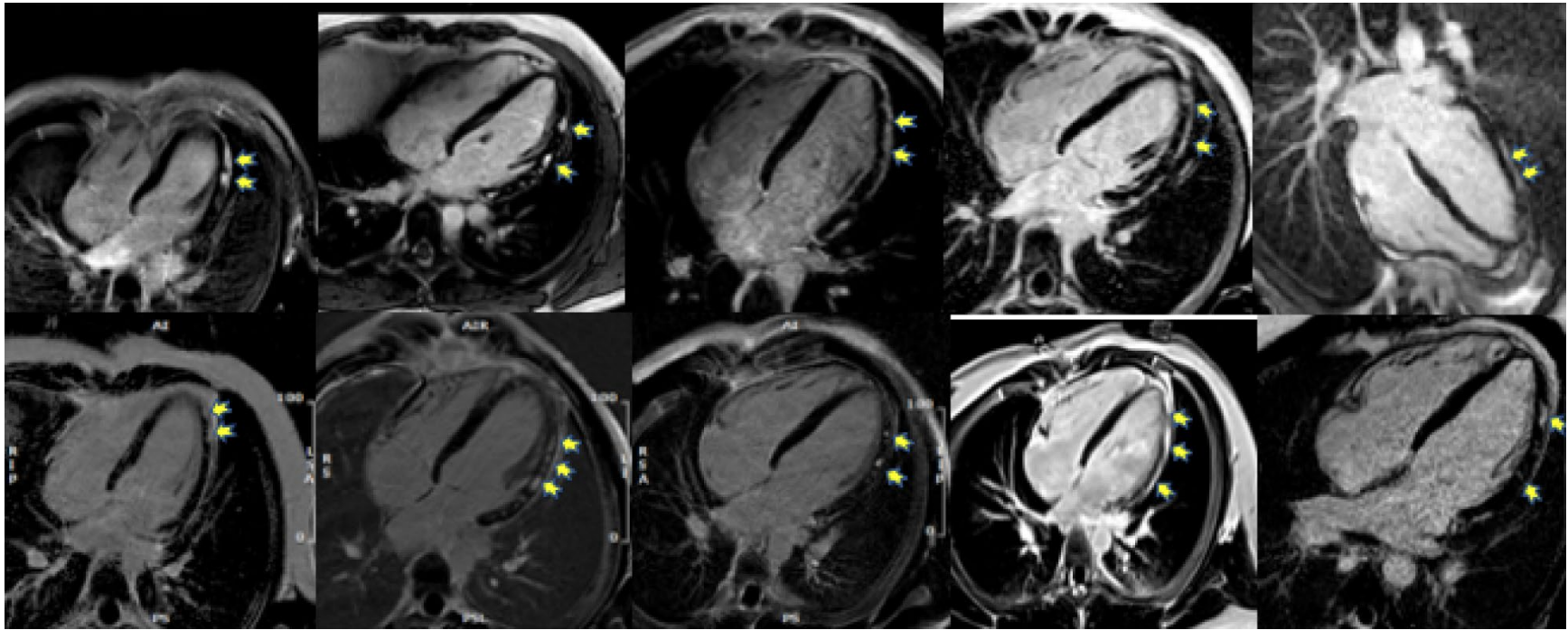


Figure 5. CMR examples illustrating LGE in C-VAM cohort (4 chamber view) The pattern of LGE is notably similar across all patients with enhancement in a subepicardial and mid myocardial pattern noted along the lateral and inferior walls (yellow arrows).

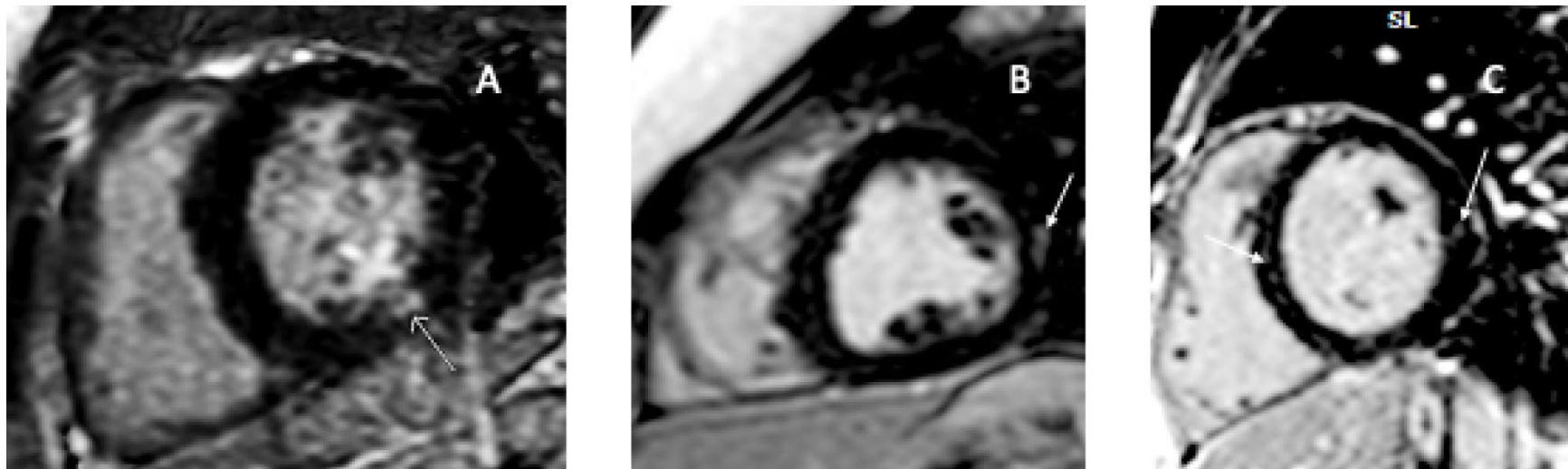


Figure 6. CMR images in three children hospitalized for MIS-C (A-C) demonstrating trivial, focal mid-myocardial LGE (white arrows). All 3 patients presented with at least moderate ventricular dysfunction, required inotropic support, including one needing extracorporeal membrane oxygenation ECMO (B)

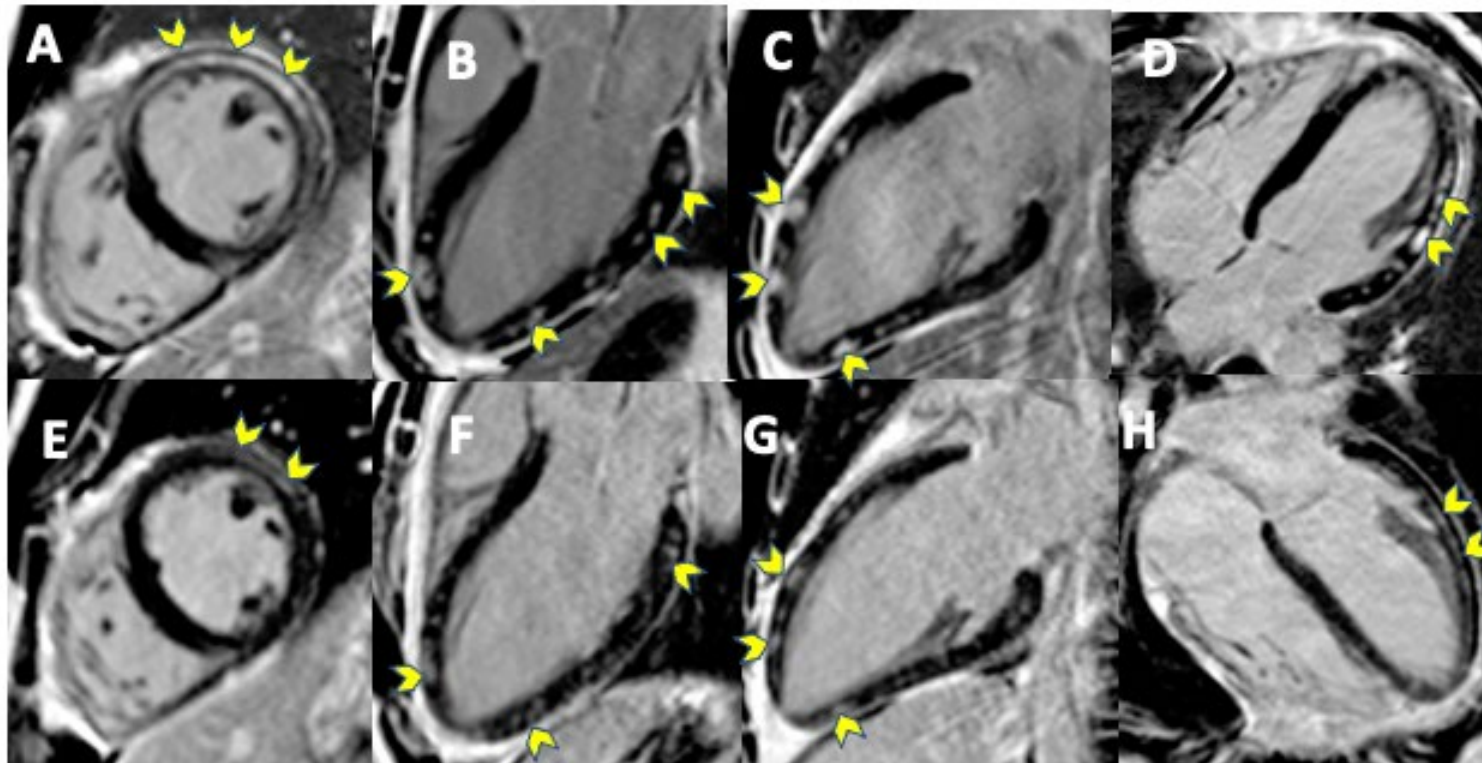


Figure 7. CMR in a COVID-19 vaccine associated myocarditis patient, at the time of diagnosis (A-D) and 8 weeks post diagnosis (E-H). There is notable persistence of myocardial late gadolinium enhancement (yellow arrows) with mild improvement.

Appendix: CMR Tissue Characterization^{4,5,6,23}

In acute myocarditis, expected tissue pathology includes interstitial/intracellular edema, hyperemia, capillary leak and in severe cases, cardiomyocyte necrosis and subsequent fibrosis.

Cardiac magnetic resonance is useful to visualize tissue changes. It can demonstrate markers of inflammation as well as cardiomyocyte damage.

In inflammation, increased permeability of cellular membrane results in edema. Imaging markers for edema include high signal intensity of cardiac muscle compared to skeletal muscle on T2-weighted imaging (Figure 3 A, B) or increased T2 relaxation time on T2 mapping (Figure 3 C). Rapid uptake of contrast in the myocardium (early gadolinium enhancement) is a sign of hyperemia/capillary leak.

Areas of acute myocardial injury/necrosis or subsequent scarring are detected by contrast retention 10 to 15 minutes after injection of gadolinium contrast agent indicated by late gadolinium enhancement (LGE). (Figure 3 D, Figures 4-7)

As per the 2009 Lake Louise criteria, in clinically suspected cases of myocarditis, the diagnosis is likely if 2 of 3 criteria from elevated signal on T2-weighted imaging, early gadolinium enhancement, and late gadolinium enhancement were present. In 2018, these criteria were updated to include edema markers such as T2 time and fibrosis markers including T1 time, and extracellular volume (ECV) fraction for improved diagnostic accuracy.

COVID-19 Vaccination-Associated Myocarditis in Adolescents

Supriya S. Jain, Jeremy M. Steele, Brian Fonseca, Sihong Huang, Sanket Shah, Shiraz A. Maskatia, Sujatha Buddhé, Nilanjana Misra, Preeti Ramachandran, Lasya Gaur, Parham Eshtehardi, Shafkat Anwar, Neeru Kaushik, Frank Han, Nita Ray Chaudhuri and Lars Grosse-Wortmann

Pediatrics originally published online August 13, 2021;

Updated Information & Services

including high resolution figures, can be found at:
<http://pediatrics.aappublications.org/content/early/2021/08/12/peds.2021-053427.citation>

Permissions & Licensing

Information about reproducing this article in parts (figures, tables) or in its entirety can be found online at:
<http://www.aappublications.org/site/misc/Permissions.xhtml>

Reprints

Information about ordering reprints can be found online:
<http://www.aappublications.org/site/misc/reprints.xhtml>

American Academy of Pediatrics

DEDICATED TO THE HEALTH OF ALL CHILDREN®



PEDIATRICS®

OFFICIAL JOURNAL OF THE AMERICAN ACADEMY OF PEDIATRICS

COVID-19 Vaccination-Associated Myocarditis in Adolescents

Supriya S. Jain, Jeremy M. Steele, Brian Fonseca, Sihong Huang, Sanket Shah, Shiraz A. Maskatia, Sujatha Buddhé, Nilanjana Misra, Preeti Ramachandran, Lasya Gaur, Parham Eshtehardi, Shafkat Anwar, Neeru Kaushik, Frank Han, Nita Ray Chaudhuri and Lars Grosse-Wortmann

Pediatrics originally published online August 13, 2021;

The online version of this article, along with updated information and services, is located on the World Wide Web at:

<http://pediatrics.aappublications.org/content/early/2021/08/12/peds.2021-053427.citation>

Pediatrics is the official journal of the American Academy of Pediatrics. A monthly publication, it has been published continuously since 1948. Pediatrics is owned, published, and trademarked by the American Academy of Pediatrics, 345 Park Avenue, Itasca, Illinois, 60143. Copyright © 2021 by the American Academy of Pediatrics. All rights reserved. Print ISSN: 1073-0397.

American Academy of Pediatrics

DEDICATED TO THE HEALTH OF ALL CHILDREN®

