

BRIEF REPORTS | ARTICLES IN PRESS

Persistent Cardiac MRI Findings in a Cohort of Adolescents with post COVID-19 mRNA vaccine myopericarditis

Jenna Schauer, MD   • Sujatha Buddhe, MD, MS • Avanti Gulhane, MD, DNB, FSCMR • ...

Sathish Mallenahalli Chikkabyrappa, MD • Yuk Law, MD • Michael A. Portman, MD • Show all authors

Published: March 25, 2022 • DOI: <https://doi.org/10.1016/j.jpeds.2022.03.032>

Abbreviations:

[Late gadolinium enhancement \(LGE\)](#), [Coronavirus disease of 2019 \(COVID-19\)](#), [Nonsteroidal anti-inflammatory drugs \(NSAIDs\)](#), [Intravenous immunoglobulin \(IVIG\)](#), [Left ventricle \(LV\)](#), [Left ventricular ejection fraction \(LVEF\)](#), [Global Longitudinal Strain \(GLS\)](#)

Myopericarditis, , has emerged as an important adverse event following COVID-19 mRNA vaccination, particularly in adolescents [\[\[1\]\]](#). Patients typically exhibit chest pain and an elevated serum troponin level in the days following the COVID-19 mRNA vaccine. They usually are hemodynamically stable, and symptoms and cardiac biomarkers normalize within a few days [\[\[2\]\]](#). cardiac magnetic resonance studies, when performed early, frequently demonstrate abnormalities such as edema and late gadolinium enhancement (LGE), meeting Lake Louise Criteria for diagnosing myocarditis noninvasively [\[\[2\],\[3\]\]](#). In classical myocarditis LGE can be predictive of a poor outcome [\[\[5\]\]](#). Little is known about the prognostic value or expected evolution of these CMR abnormalities associated with post-COVID-19 mRNA vaccine myopericarditis. In this case series we report the evolution of CMR imaging compared with initial, acute phase, CMR in our cohort of patients with myopericarditis post COVID-19 mRNA vaccine.



Methods

This case review includes patients younger than 18 years of age presenting to Seattle Children's Hospital with chest pain and elevated serum troponin level from April 1, 2021 to January 7, 2022 within one week of receiving the second dose of the Pfizer COVID-19 mRNA vaccine. Institutional Review Board approval was obtained. All patients were evaluated by a pediatric cardiologist, underwent ECG and echocardiogram, and were admitted for observation with telemetry, serial troponin measurements, and repeat cardiac testing as needed. All patients underwent CMR within 1 week of initial presentation and had repeat CMR imaging at 3-8 months follow up. CMR was performed on a 1.5 T Siemens scanner. CMR analysis was performed using CVI42 (version 5.11.4, Circle Cardiovascular Imaging Inc., Alberta Canada). Patients were excluded if they did not undergo CMR or did not have a follow up CMR. Initial and follow up CMR data for each patient were reviewed and compared using paired Student *t*-test. Statistical significance was defined as a $p < 0.05$. Statistical analysis was performed using SPSS 27 (SPSS Inc., Chicago, IL).

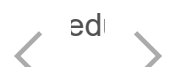Results

A total of 35 patients with the diagnosis of myopericarditis associated with Pfizer COVID-19 mRNA vaccine are followed at our institution. Twelve patients were excluded as they never had CMR due to delayed presentation after initial symptoms resolved or admission to other centers. Six patients were excluded as they did not have a follow up CMR, either because they followed up out of state or a study is still pending. One patient was excluded as initial CMR was performed 3 weeks after presentation. Sixteen patients who had both acute phase and follow-up CMR available for review comprised the final cohort. This group had a median age of 15 years (range, 12-17), were mostly male ($n=15$, 94%), white and non-Hispanic ($n=14$, 88%). One patient was Asian and one patient was American Indian. Median time to presentation from the second dose of the Pfizer COVID-19 mRNA vaccine was 3 days (range 2-4 days). All patients had chest pain. The most common other presenting symptoms were fever ($n=6$, 37.5%) and shortness of breath ($n=6$, 37.5%). All patients had elevated serum troponin levels (median 9.15 ng/mL, range 0.65-18.5, normal < 0.05 ng/mL). Twelve patients had c-reactive protein (CRP) measured with median value 3.45 mg/dL, range 0-6.5 mg/dL, normal < 0.08 mg/dL.

Ten (62.5%) patients had an abnormal electrocardiogram (ECG), with the most common finding being diffuse ST segment elevation. All patients had an echocardiogram on admission; 14/16



had normal left ventricular (LV) systolic function; two patients demonstrated normal LV systolic function with no dilation. Left ventricular ejection fraction (LVEF) for these 10



was 45% and 53% (normal > 55%). Median left LVEF was 59% (range 45-69%). No patients had pericardial effusion.

The initial CMRs were performed within 1 week of presentation (median 2, range 0-7 days). All were abnormal; all showed evidence of edema by T2 imaging and 15/16 had LGE in a patchy subepicardial to transmural pattern with predilection for the inferior LV free wall. Distribution of LGE can be seen in [Figure 1](#). LV regional wall motion abnormalities were noted in 2 patients. CMR median LVEF% was 54%, range 46-63%. CMR LVEF was mildly decreased in 7 patients. CMR global longitudinal strain (GLS%) measurements were abnormal in 12 patients (median -16.1%, range -13.2% to -18.1%, normal <-18%).


 Figure thumbnail gr1

Figure 1 Distribution of Late Gadolinium Enhancement (LGE) in American Heart Association Myocardial Segments[[12]].

Figure shows segment with number of patients and percent of cohort.

[View Large Image](#) | [Download Hi-res image](#) | [Download \(PPT\)](#)

All patients were treated with nonsteroidal anti-inflammatory drugs (NSAIDs): 75% (n=12) received scheduled dosing (mostly, 10 mg/kg ibuprofen every 8 hours) with the remaining 4 receiving NSAIDs as needed for pain. The median time from vaccination to NSAID initiation was 2.5 days (range 0-4 days) and from symptom onset to NSAID initiation was 1 day (range 0-4 days). The two patients who presented with echocardiographic LV dysfunction were treated with intravenous immunoglobulin (IVIG) plus a corticosteroid per our institutional pathway for treatment of myocarditis[[2]]. One additional patient received IVIG without corticosteroids. Median hospital length of stay was 2 days (range 1-4 days) with no ICU admission and no significant morbidity or mortality. All patients had resolution of chest pain and down-trending serum troponin level prior to discharge.

All patients underwent follow up CMR at 3-8 months after their initial study (median 3.7 months, range 2.8-8.1 months). The results are compared in [Table I](#). Follow up CMR LVEF ($57.7 \pm 2.8\%$) was significantly improved from initial ($54.5 \pm 5.5\%$, $p < 0.05$), and none of the patients had regional wall motion abnormalities. LVEF by echocardiogram was normal for all patients at the time of follow up. Eleven patients (68.8%) had persistent LGE, although there was a significant decrease in the quantifiable LGE% ($8.16 \pm 5.74\%$) from the initial study ($13.77 \pm 8.53\%$, $p < 0.05$). Cardiac edema

and in all but one patient. GLS% remained abnormal in most patients (75%, mean $-16.0 \pm 1.7\%$) at follow up without significant change from the initial study (-16.0 ± 1.7 , $p = 0.6$)

of initial and follow up CMR images are shown in [Figure 2](#). The patient who received IVIG alone and one patient who received IVIG plus corticosteroid had resolution of LGE, and the other had persistence of LGE.

Table 1 Covid Vaccine-Associated Myopericarditis Findings in 16 patients

	Initial (Mean±SD)	Follow up (Mean±SD)	P value
Echocardiographic LVEF %	59.4±6.0	62.6±2.8	<0.05
Electrocardiogram	10 (62.5%)		
Abnormal			
Normal	6 (37.5%)		
Peak Serum Troponin (ng/mL)	9.0± 5.2		
CMR LVEF %	54.5 ± 5.5	57.7 ±2.7	<0.05
CMR LGE % (n=15*)	13.5± 8.3	7.7 ± 5.7	<0.001
CMR global longitudinal strain % (n=15*)	-16.0 ± 1.7	-16.4 ± 2.1	0.5

*Initial source images were not available for reanalysis for one patient.

LVEF% = LV ejection fraction

LGE %= percentage of late gadolinium enhancement

ent

CMR = Cardiac MRI



[Table in a new tab](#)



 Figure thumbnail gr2

Figure 2 CMR images from 3 days after admission of a 16-year-old male who presented to emergency room with chest pain and elevated troponin 3 days after receiving Pfizer COVID-19 mRNA vaccine. Initial CMR. 1a and 1b. subepicardial to midmyocardial LGE in inferior and inferolateral LV wall from base to apex (arrows). 1c shows T2 hyper-intensity in similar segments, consistent with edema. 1d, 1e and 1f. Follow up CMR 4.4 months later. LGE still persistent but decreased from 26% to 19.84% (arrows), LVEF remained stable at 58%. There is improved T2 hyperintensity.

[View Large Image](#) | [Download Hi-res image](#) | [Download \(PPT\)](#)

Eight patients (5 of whom had persistent LGE) underwent 24-hour cardiac rhythm monitoring, all of which studies were normal. Six patients, all with persistent LGE, underwent exercise tests, all of which were normal. Four patients complained of intermittent chest pain at follow up with no identifiable abnormality on evaluation; no therapy or intervention was required. No patient received heart failure medication.

DISCUSSION

We previously reported 15 patients with clinically suspected SARS-CoV-2 mRNA vaccine induced myopericarditis. All patients had an abnormal CMR, with edema and or LGE in addition to clinical symptoms and troponin elevation, and some had abnormal ECG or echocardiogram [\[\[3\]\]](#). We have since established a clinical protocol for serial CMR performance in these patients consistent with the 2021 American Heart Association (AHA) statement that stressed the risk of sudden cardiac death, particularly with exercise, while active inflammation is present. [\[\[6\]\]](#). our patients were restricted from exercise on discharge. Repeat CMR was performed within 3-6 months to guide next clinical decision-making steps; timing was modified in some individuals based on scanner accessibility and safety precautions during the COVID-19 pandemic. Although symptoms were transient and most patients appeared to respond to treatment (solely with NSAIDs), we demonstrated persistence of abnormal findings on CMR at follow up in most patients, albeit with improvement in extent of LGE.

CMR has increasingly been identified as an important diagnostic tool for myocarditis given its ability



tify subclinical injury and fibrosis by markers of LGE and edema. CMR also has



in longitudinal follow up of patients with myocarditis to help therapeutic management, although exact screening protocols remain controversial[[6]].

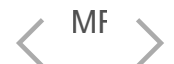The presence of LGE is an indicator of cardiac injury and fibrosis and has been strongly associated with worse prognosis in patients with classical acute myocarditis. In a meta-analysis including 8 studies, Yang et al found that presence of LGE is a predictor of all cause death, cardiovascular death, cardiac transplant, rehospitalization, recurrent acute myocarditis and requirement for mechanical circulatory support[[5]]. Similarly, Georgiopoulos et al found presence and extent of LGE to be a significant predictor of adverse cardiac outcomes in an 11 study meta-analysis[[7]].

The persistence of LGE over time and its prognostic value is less well established. Malek et al found that in a cohort of 18 patients with myocarditis, nearly 70% had persistent CMR changes at a median follow-up time of 7 months[[5]]. Dubey et al found similar findings in their cohort of 12 pediatric patients, with persistence of LGE in all patients despite resolution of edema[[9]]. Prognostic meaning of LGE in vaccine associated myopericarditis requires further study.

Strain analysis by CMR also has been shown to have prognostic utility in myocarditis even in the setting of normal LV function[[10]]. Strain testing can be performed without use of contrast material and can be particularly useful in situations where contrast administration is challenging or contraindicated. Notably, in our cohort, though there was significant reduction in LGE at follow up, abnormal strain persisted for the majority of patients at follow up.

This study has certain limitations. Patients who did not seek medical attention during acute illness or did not present with significant symptoms and require hospitalization were not captured, and their disease course may be different. Incomplete CMR data on other patients precludes extrapolation of our CMR findings to all who experienced mRNA vaccine-related myopericarditis. In addition, follow-up CMR timeframes varied from patient to patient making it difficult to predict the timing of CMR changes over time. the total number of patients reported is small, limiting ability to draw conclusions about the effect of treatment modalities or to generalize regarding outcomes of vaccine-associated myopericarditis.

In a cohort of adolescents with COVID-19 mRNA vaccine-related myopericarditis, a large portion have persistent LGE abnormalities, raising concerns for potential longer-term effects. Despite these persistent abnormalities, all patients had rapid clinical improvement and normalization of echocardiographic measures of systolic function. For patients with short acute illness, no dysfunction demonstrated by echocardiogram at presentation and resolution of symptoms at follow up. Return to sports was guided by normalization of CMR alone. In patients with persis



abnormalities we performed exercise stress testing prior to sports clearance per myocarditis recommendations[[6]]. We plan to repeat CMR at 1 year post-vaccine for our cohort to assess for resolution or continued CMR changes.

The CDC notes that even though the absolute risk for myopericarditis following mRNA COVID-19 vaccine is small, the relative risk is higher for particular groups, including males 12-39 years of age. Some studies have suggested that increasing the interval between the first and second dose may reduce the incidence of myopericarditis in this population [[11]]. These data led to an extension in CDC recommended dosing interval between dose 1 and dose 2 to 8 weeks. Further follow up assessment and larger multicenter studies are needed to determine the ultimate clinical significance of persistent CMR abnormalities in patients with post COVID-19 vaccine myopericarditis

Uncited reference

[[4]], [[8]].

REFERENCES

1. Gargano JW, Wallace M, Hadler SC, Langley G, Su JR, Oster ME, et al. Morbidity and Mortality Weekly Report Use of mRNA COVID-19 Vaccine After Reports of Myocarditis Among Vaccine Recipients: Update from the Advisory Committee on Immunization Practices-United States, June 2021 2021;70. https://doi.org/10.1161/CIR.000000000000239?url_.

[View in Article](#) ^

[Google Scholar](#)

2. Kohli U. • Desai L. • Chowdhury D. • Harahsheh A.S. • Yonts A.B. • Ansong A. • et al. **mRNA Coronavirus-19 Vaccine–Associated Myopericarditis in Adolescents: A Survey Study.** *The Journal of Pediatrics.* 2021; <https://doi.org/10.1016/j.jpeds.2021.12.025>

[View in Article](#) ^

[Google Scholar](#)



3. Truong D.T. • Dionne A. • Muniz J.C. • McHugh K.E. • Portman M.A. • Lambert L.M. • et al.

Clinically Suspected Myocarditis Temporally Related to COVID-19 Vaccination in Adolescents and Young Adults.

Circulation. 2021;

<https://doi.org/10.1161/circulationaha.121.056583>

[View in Article](#) ^

[Google Scholar](#)

4. Schauer J. • Buddhe S. • Colyer J. • Sagiv E. • Law Y. • Mallenahalli Chikkabyrappa S. • et al.

Myopericarditis After the Pfizer Messenger Ribonucleic Acid Coronavirus Disease Vaccine in Adolescents.

Journal of Pediatrics. 2021; **238**: 317-320

<https://doi.org/10.1016/j.jpeds.2021.06.083>

[View in Article](#) ^

[Google Scholar](#)

5. Yang F. • Wang J. • Li W. • Xu Y. • Wan K. • Zeng R. • et al.

The prognostic value of late gadolinium enhancement in myocarditis and clinically suspected myocarditis: systematic review and meta-analysis.

European Radiology. 2020; **30**: 2616-2626

<https://doi.org/10.1007/s00330-019-06643-5>

[View in Article](#) ^

[Google Scholar](#)

6. Law Y.M. • Lal A.K. • Chen S. • Čiháková D. • Cooper L.T. • Deshpande S. • et al.
Diagnosis and Management of Myocarditis in Children: A Scientific Statement from the American Heart Association.

Circulation. 2021; (E123–35)

<https://doi.org/10.1161/CIR.0000000000001001>



[View in Article](#) ^



[Google Scholar](#)

7. Georgiopoulos G. • Figliozzi S. • Sanguineti F. • Aquaro G.D. • di Bella G. • Stamatelopoulos K. • et al.

Prognostic Impact of Late Gadolinium Enhancement by Cardiovascular Magnetic Resonance in Myocarditis: A Systematic Review and Meta-Analysis.

Circulation: Cardiovascular Imaging. 2021; : 55-65

<https://doi.org/10.1161/CIRCIMAGING.120.011492>

[View in Article](#) ^

[Google Scholar](#)

8. Małek Ł.A. • Kamińska H. • Barczuk-Fałęcka M. • Ferreira V.M. • Wójcicka J. • Brzewski M. • et al.

Children With Acute Myocarditis Often Have Persistent Subclinical Changes as Revealed by Cardiac Magnetic Resonance.

Journal of Magnetic Resonance Imaging. 2020; **52**: 488-496

<https://doi.org/10.1002/jmri.27036>

[View in Article](#) ^

[Google Scholar](#)

9. Dubey S. • Agarwal A. • Nguyen S. • Adebo D.

Persistence of Late Gadolinium Enhancement on Follow-Up CMR Imaging in Children with Acute Myocarditis.

Pediatric Cardiology. 2020; **41**: 1777-1782

<https://doi.org/10.1007/s00246-020-02445-5>

[View in Article](#) ^

[Google Scholar](#)

10. Chen Y. • Sun Z. • Xu L. • Liu J. • Li Y. • Zhang N. • et al.

Diagnostic and Prognostic Value of Cardiac Magnetic Resonance Strain in Suspected Myocarditis With Preserved LV-EF: A Comparison Between Patients With Negative and Positive Late Gadolinium Enhancement Findings.



Journal of Magnetic Resonance Imaging. 2021;

<https://doi.org/10.1002/jmri.27873>

[View in Article](#) 

[Google Scholar](#)

11. Moulia D. Myocarditis and COVID-19 vaccine intervals: international data and policies. n.d.

[View in Article](#) 

[Google Scholar](#)

12. Cerqueira M.D. • Weissman N.J. • Dilsizian V. • Jacobs A.K. • Kaul S. •

Laskey W.K. • et al.

Standardized Myocardial Segmentation and Nomenclature for Tomographic Imaging of the Heart.

Circulation. 2002; **105**: 539-542

<https://doi.org/10.1161/hc0402.102975>

[View in Article](#) 

[Google Scholar](#)

Article Info

Publication History

Accepted: March 23, 2022

Received in revised form: March 17, 2022

Received: February 7, 2022

Publication stage

In Press Accepted Manuscript

Footnotes

No funding was received for this research



Authors declare no conflicts of interest. Abstract



We describe the evolution of Cardiac MRI (CMR) findings in 16 patients, 12-17 years of age, with myopericarditis after the second dose of the Pfizer mRNA COVID-19 vaccine. Although all patients showed rapid clinical improvement, many had persistent CMR findings at 3-8 month follow up.

Identification

DOI: <https://doi.org/10.1016/j.jpeds.2022.03.032>

Copyright

Published by Elsevier Inc.

ScienceDirect

[Access this article on ScienceDirect](#)

Figures

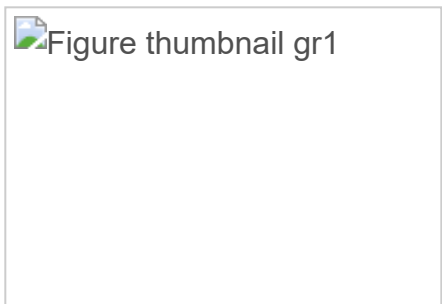
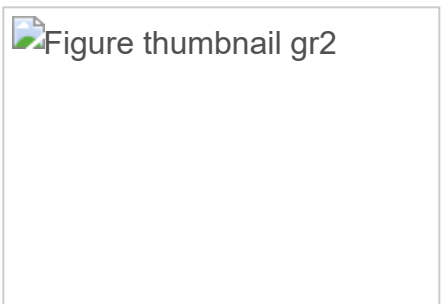
Figure thumbnail gr1Figure thumbnail gr2

Figure 1 Distribution of Lat... **Figure 2** CMR images fro...

Tables

[Table 1 : Covid Vaccine-Associated Myopericarditis Findings in 16 patients](#)

Related Articles



Home	Association Pages	Submit a Manuscript	JOURNAL INFO	Contact Us
ARTICLES AND ISSUES	Shared Science	Promote Your Research	About The Journal	MEDIA/PRESS
Articles Online First	Insights and Images Quiz Archives	Publishing Campus	About Open Access	Press Releases
Current Issue	REACH	Resources for Authors	Career Opportunities	Social Media Accounts
List of Issues	FOR AUTHORS	FOR READERS	Editorial Board	Subscribe
COLLECTIONS	Guide for Authors	Access this journal via ScienceDirect	Editorial Board Conflicts of Interest	MY ACCOUNT
Current Best Evidence	Publication Ethics	Announcements and Upcoming Events	Information for Advertisers	My Account
Rediscovering the Physical Exam	About Open Access	Sign up as a reviewer	Journal Access	New Content Alerts
AMSPDC Articles	Permission to Reuse		Journal Insights	FOLLOW US
European Paediatric	Researcher Academy		More Information	Facebook
				Twitter

We use cookies to help provide and enhance our service and tailor content. To update your cookie settings, please visit the [Cookie Settings](#) for this site.

Copyright © 2022 Elsevier Inc. except certain content provided by third parties. The content on this site is intended for healthcare professionals.

[Privacy Policy](#) [Terms and Conditions](#) [Accessibility](#) [Help & Contact](#)

